

Research article

Metastatising osteosarcoma in an eastern white pelican (*Pelecanus onocrotatus*)

F.M. Molenaar¹, T. Strike¹, J. Dodds¹, K. Berry¹, T. Whitbread² and J. Graham¹

¹Zoological Society of London, Whipsnade Zoo, Whipsnade, Dunstable, Bedfordshire, LU6 2LF

²Abbey Veterinary Services, 89 Queen Street, Newton Abbot, Devon, TQ12 2BG

Correspondence: fieke.molenaar@zsl.org

Keywords:

great white pelican, myocardium, skeletal musculature

Article history:

Received: 15 April 2014

Accepted: 13 May 2015

Published online: 23 July 2015

Abstract

A 15-month old captive born Eastern white pelican (*Pelecanus onocrotatus*) with an abnormal gait had a firm swelling of the right stifle that was unresponsive to conservative treatment with NSAIDs. Radiography of the leg showed disruption of the osseous detail of the distal femur and proximal tibiotarsus with a marked periosteal reaction, marked soft tissue swelling surrounding the right stifle and mottled increased radiodensity of these soft tissues. Despite medical treatment, the immobility of the leg progressed, inappetence set in and the bird was euthanased. On post-mortem examination there was a large ossified mass at the right stifle and additional well circumscribed masses were evident in the leg and wing musculature, pectoral muscles and myocardium. Further masses were present in the liver and in one kidney. Histological examination identified the stifle mass as an osteosarcoma. The various masses found in the musculature, liver and kidney were constructed of similar cells and considered metastases. The predilection of the metastases for muscular tissue, including the myocardium, is unusual and has not previously been described in birds.

Introduction

The eastern white pelican (*Pelecanus onocrotatus*, also known as the great white pelican) is a large, enigmatic bird that is a resident of Africa but can also be found as a migratory species in eastern Europe (del Oyo et al. 1992). It is a species frequently kept in zoos and classified as Least Concern on the IUCN Red List (BirdLife International 2012).

Case history

A 15-month old captive born, wing-clipped (feather-clipped, left), hand-reared eastern white pelican was presented with an abnormal gait of one week's duration. On examination there was a firm, marked swelling of the right stifle and an inability to fully extend the right hip and stifle joint. There was discomfort on manipulation of the leg, and no evidence of external trauma. Treatment with non-steroidal anti-inflammatories was instigated (meloxicam 0.2 mg/kg once daily per os, Metacam®, Boehringer-Ingelheim). As no improvement could be seen four days later, the bird was examined under general anaesthetic

(propofol 3 mg/kg i.v., Vetofol®, Norbrook, followed by isoflurane in O₂, Isoflo®, Abbot). Haematology and biochemistry were unremarkable, with a PCV of 34% and a mildly elevated WBC count of 27*10⁹/L (ISIS reference range: 2.45–25.22*10⁹/L), with a differential of 66% heterophils, 26% lymphocytes, 5% monocytes and 3% basophils. There had been a 10% loss of body weight over a period of five months. Radiography showed disruption of the osseous detail of the distal femur and proximal tibiotarsus with a marked periosteal reaction, marked soft tissue swelling surrounding the right stifle and mottled increased radiodensity of these soft tissues (Fig. 1). Subsequent treatment with pentosan (4 mg/kg i.m., Cartrophen®, Forte), antibiotics (marbofloxacin 10 mg/kg once daily per os, Marbocyl®, Vetoquinol) and anti-inflammatories (meloxicam 0.3 mg/kg once daily per os, Metacam®, Boehringer-Ingelheim) proved ineffective. Progressive immobility, inappetence and further condition loss, up to 17% in total, prompted euthanasia of the pelican (pentobarbitone 170 mg/kg i.v., Pentoject®, Animal Care).

Post-mortem examination showed moderate subcutaneous fat deposits and a good muscular condition. There was

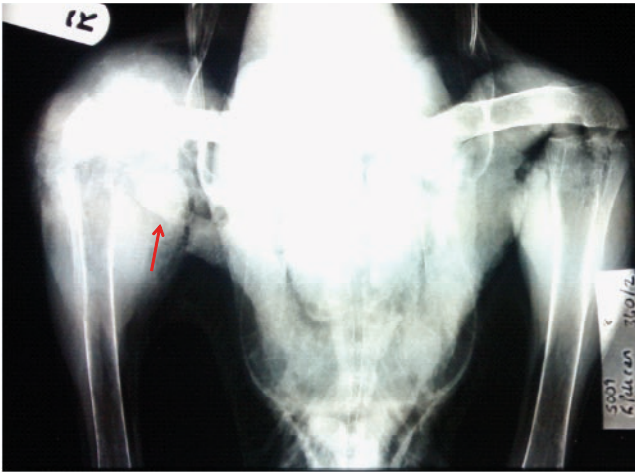


Figure 1. Radiograph of the pelvic area and both stifles. Note the increased radiodensity around the right stifle (marked R) compared to the left, with disruption of the osseous detail of the distal femur and proximal tibiotarsus, with additional radiodense structures present in the soft tissue immediately surrounding the joint (arrow).

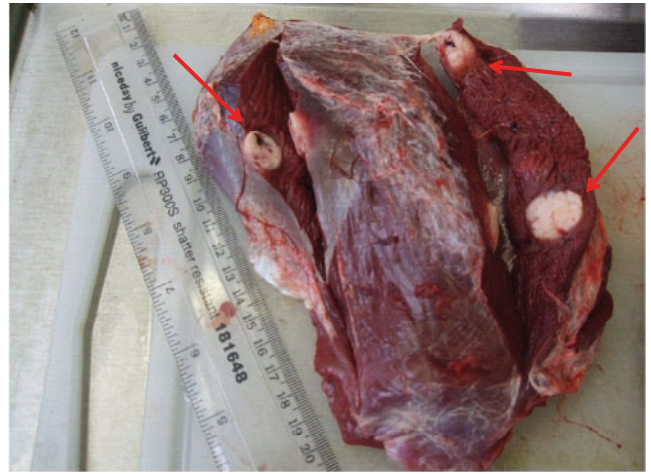

Figure 2. Three irregular intramuscular masses were found in the right superficial pectoral muscle varying in size from approximately 13–17 mm (arrows). These masses were firm on cross section and areas of haemorrhage were visible.

subcutaneous bruising of the lateral aspect of the right leg, caudal aspect of the tail and caudal aspect of the left stifle joint, suggestive of blunt trauma. On the lateral, medial and caudal aspect of the right stifle, there was a firm irregular mass incorporating the distal half of the femur. Additionally, there were several beige, well demarcated, irregular masses of approximately 10–30 mm diameter present in the soft tissues and musculature lateral to the stifle. The masses present on the lateral aspect were firm on cut surface with a bony appearance; those present on the medial aspect were less firm and had haemorrhagic centres. A cross section through the distal femur mass revealed a uniformly bony cut surface with loss of the normal cortical architecture and medullary cavity.

Single or multiple pale, firm, irregular masses measuring up to 21 mm were also present in the leg musculature, the flexor muscle of the right elbow, the right and left superficial pectoral muscles (Fig. 2) and in the intra-coelomic fat.

There was a single intra-myocardial mass present of approximately 40 mm diameter on the ventral aspect of the heart, near the apex, full thickness, penetrating into the right ventricle. There were various intra-hepatic firm masses present, varying in size from 6–27 mm, with associated haemorrhage at the liver surface. The surrounding hepatic tissue was friable. The spleen was swollen, approximately 32 mm in length, with a mottled, granular appearance on cross section. The left kidney appeared enlarged and friable. The right kidney was ablated by two large masses of 60 mm diameter (mostly haemorrhagic tissue), and 33 mm diameter (mixed renal, haemorrhagic and firm beige tissue) respectively. Impression smears of the femoral and muscular masses were negative for acid fast organisms on Ziehl-Neelsen staining. Histologically, femoral mass consisted of nodules of spindle-shaped to occasionally more rounded cells with scant to moderate amounts of eosinophilic cytoplasm and plump oval nuclei exhibiting mild to moderate anisokaryosis. Nuclei often had a prominent eosinophilic nucleolus. Twenty mitotic figures were noted in a count of ten high powered fields. In many areas cells were surrounded and/or entrapped by osteoid matrix. In the kidneys, there was focal effacement of normal renal architecture by a neoplastic mass composed of sheets of haphazardly arranged

cells as described in the femoral mass, equally surrounded by osteoid matrix. Similar histological features were demonstrated in the masses found in the myocardium (Fig. 3), pectoral muscle and liver. Additionally, there were aggregates of extramedullary haematopoietic tissue in the portal areas in the liver. Considering the characteristics of tumour cells in the femoral bone and other tissues, the neoplastic masses were diagnosed as a metastasising osteosarcoma.

Discussion

Neoplasms previously found in pelicans include a squamous cell carcinoma (Pesaro et al. 2009) and a malignant T-cell lymphoma (Schmidt et al. 2012), both described in pink-backed pelicans (*Pelecanus rufescens*). Where bone tumours in birds are concerned, the literature is sparse. Secondary bone tumours have

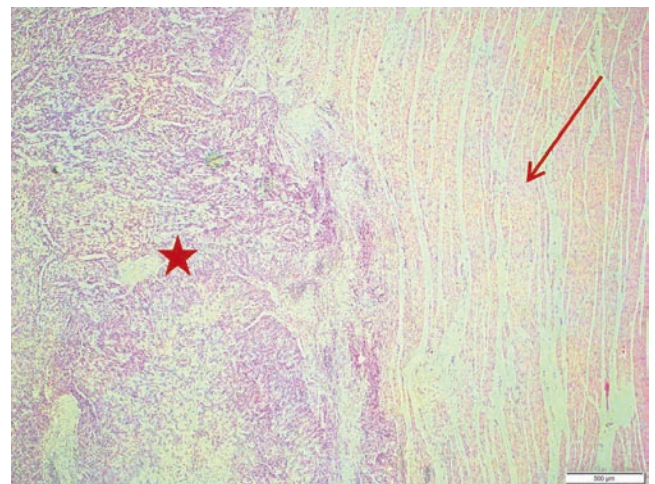


Figure 3. Histological appearance of myocardium (normal myocardial fibres = arrow) with embedded neoplastic mass (pleomorphic cells surrounded by osteoid matrix = star).

thus far only been described in macaws (Fredholm et al. 2012) and owls (Rettenmund et al. 2010), and primary bone tumours are equally rare. Benign osteomas have been found in a blue-fronted Amazon parrot (*Amazona aestiva*) (Cardoso et al. 2013) and in a barred owl (*Strix varia*) (Hahn et al. 1998) and single malignant bone tumours have been seen in chickens (Dittmer et al. 2012), an American robin (*Tuiurdus migratorius*) (Hartup and Steinberg 1996) and a blue crane (*Anthropoides paradiseus*) (Churgin et al. 2013). A metastasising osteosarcoma has been described in a Panama boat-billed heron (*Cochlearius cochlearius*) (Liu et al. 1982), where metastases were found in bone marrow, the ovary, lung, liver and kidneys. In this pelican, it is most likely that the femoral mass had been the primary osteosarcoma. Its metastases, however, had a remarkable predilection for the myocardium and skeletal musculature without continuity with skeletal structures. Such metastases have not previously been described in birds.

References

- BirdLife International (2012) *Pelecanus onocrotalus*. *The IUCN Red List of Threatened Species*. Version 2015.2. www.iucnredlist.org (downloaded on 16 July 2015).
- Cardoso J.F., Levy M.G., Liparisi F., Romao M.A. (2013) Osteoma in a blue-fronted Amazon parrot (*Amazona aestiva*). *Journal of Avian Medicine and Surgery* 27: 218–21.
- Churgin S.M., Steinberg H., Ravi M., Hartup B.K. (2013) Sternal osteosarcoma in a blue crane (*Anthropoides paradiseus*). *Journal of Zoo and Wildlife Medicine* 44: 1075–1078.
- del Oyo J., Elliott A., Sargatal J. (1992) Order Pelecaniformes: Family Pelecanidae. In: del Oyo J., Elliott A., Sargatal J. (eds). *Handbook of the Birds of the World, Volume 1*. Barcelona: Lynx Edicions, 290–311.
- Dittmer K.E., French A.F., Thompson D.J., Buckle K.N., Thompson K.G. (2012) Primary bone tumors in birds: a review and description of two new cases. *Avian Diseases* 56: 422–426.
- Fredholm D.V., Carpenter J.W., Schumacher L.L., Moon R.S. (2012) Pulmonary adenocarcinoma with osseous metastasis and secondary paresis in a blue and gold macaw (*Ara ararauna*). *Journal of Zoo and Wildlife Medicine* 43: 909–913.
- Hahn K.A., Jones M.P., Petersen M.G., Patterson M.M. (1998) Clinical and pathological characterization of an osteoma in a barred owl. *Avian Pathology* 27: 306–308.
- Hartup B.K., Steinberg H. (1996) Osteosarcoma in an American robin (*Turdus migratorius*). *Avian Diseases* 40: 938–940.
- Liu S., Dolensek E.P., Tappe J.P. (1982) Osteosarcoma with multiple metastases in a Panama boat-billed heron. *Journal of the American Veterinary Medical Association* 181: 1396–1398.
- Pesaro S., Biancani B., Fabbri G., Rossi G. (2009) Squamous cell carcinoma with presence of poxvirus-like inclusions in the foot of a pink-backed pelican (*Pelecanus rufescens*). *Avian Pathology* 38: 229–231.
- Rettenmund C., Sladky K.K., Rodriguez D., Petersen M., Pinkerton M.E., Rao D. (2010) Pulmonary carcinoma in a great horned owl (*Bubo virginianus*). *Journal of Zoo and Wildlife Medicine* 41: 77–82.
- Schmidt V., Philipp H.C., Thielebein J., Troll S., Hebel C., Uppert H. (2012) Malignant lymphoma of T-cell origin in a Humboldt penguin (*Spheniscus humboldti*) and a pink-backed pelican (*Pelecanus rufescens*). *Journal of Avian Medicine and Surgery* 26: 101–106.